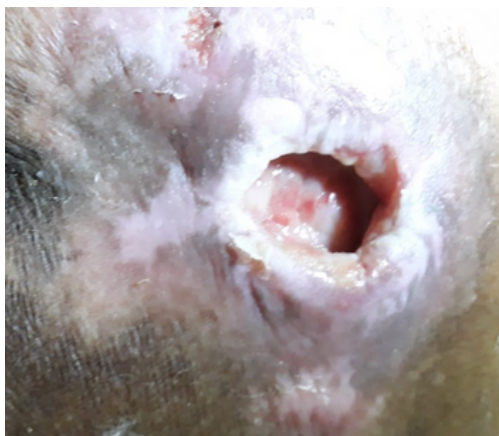


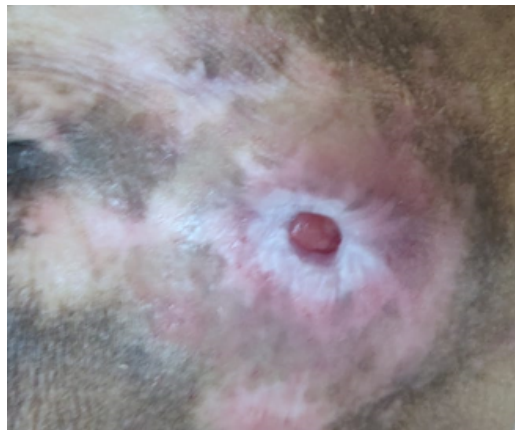CASE REPORT

AGE OF PATIENT	71 YRS
WOUND TYPE	BED SORES
AGE OF THE WOUND	1 MONTH (BEFORE SYNERHEAL TREATMENT)
WOUND LOCATION	BASE OF THE SPINE
CURRENT TREATMENT	SEESKIN P & SEESKIN PLUS

Day 1



Day 15



Day 22

